

# Piezoelectric Surgery for Exposure of Palatally Impacted Canines

VITTORIO GRENGA, MD, DDS  
MAURO BOVI, MD, DDS

**T**reatment of a palatally impacted maxillary permanent canine often involves surgical exposure of the tooth, followed by orthodontic repositioning.<sup>1-10</sup> After the elevation of a palatal flap, the overlying bone is usually removed with electric or manual instruments.

This article presents an alternative method that uses piezoelectricity to minimize trauma to the impacted tooth and the surrounding tissues. The Mectron Piezosurgery\* device contains a powerful piezoelectric handpiece with a functional frequency of 25-29kHz and a digital modulation capability of 30Hz<sup>11-14</sup> (Fig. 1). It improves surgical control by performing a precise, selective cut, using ultrasonic waves transmitted to the hard tissues through an insert mounted on the handpiece. The inserts vibrate linearly between 60 and 210 microns, providing the handpiece with power in excess of 5W (Fig. 2). A

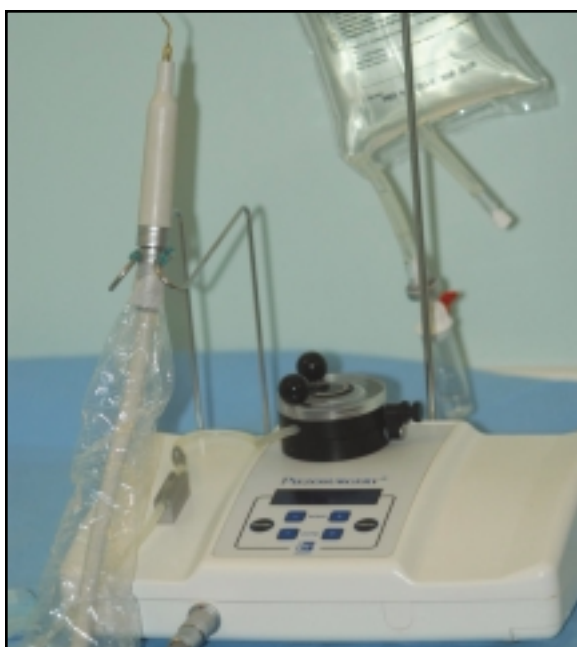

Fig. 1 Mectron Piezosurgery device.

high-powered pump emits a biocompatible .9% sodium chloride solution for cooling.

## Surgical Procedure

Local anesthesia is administered in both the upper buccal area and the palatal area near the impacted canine. A palatal intrasulcular incision is then made with a Bard-Parker\*\* No. 15 blade from the contralateral central incisor to the second premolar distal to the impacted canine, and a mucoperiosteal flap is raised (Fig. 3).

After the bone surface covering the canine crown has been located, a sufficient quantity of bone to expose the crown is removed with the OT5 insert of the piezoelectric device (Fig. 4). The crown surface is then exposed by placing the EX1 insert into the pericoronar follicular space, and the follicle is removed (Fig. 5). If necessary, the OT2 insert is used to create a guide channel through the alveolar bone (Fig. 6), which will

\*Registered trademark of Mectron Medical Technology, Via Loreto 15/A, 16042 Carasco, Italy; www.mectron.com.

\*\*Trademark of BD, 1 Becton Drive, Franklin Lakes, NJ 07417.

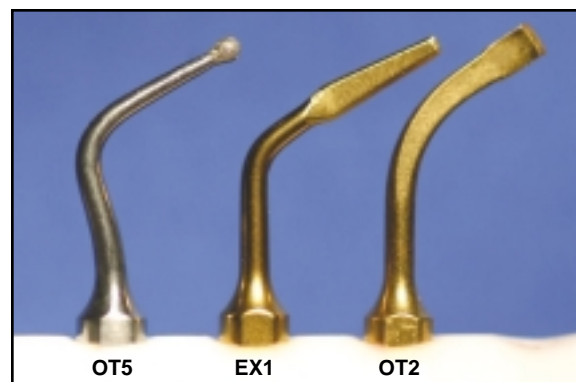


Fig. 2 Inserts for Piezosurgery handpiece: OT5 (diamond sphere), EX1 (luxator with rectilinear cut), OT2 (flat chisel with sharp titanium nitride edge).

Dr. Grenga is in the private practice of orthodontics and Dr. Bovi in the private practice of oral surgery at Via Apuania, 3, 00162 Roma, Italy; e-mail: vigrenga@tin.it.



Dr. Grenga



Dr. Bovi

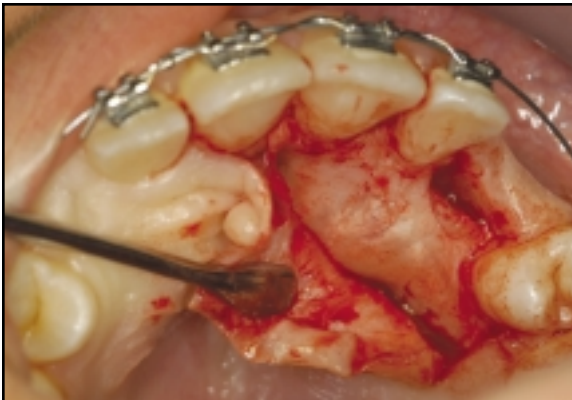

Fig. 3 Elevation of mucoperiosteal flap.

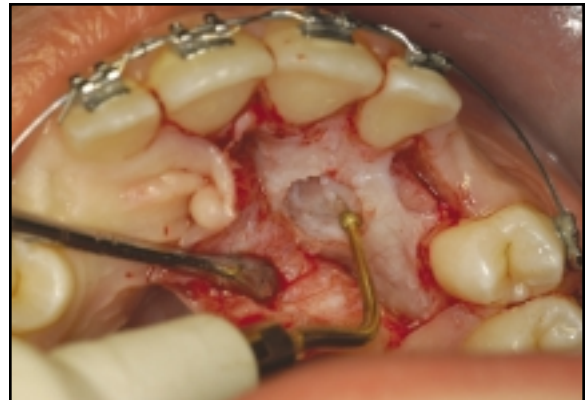

Fig. 4 Removal of bone over impacted canine using OT5 insert.

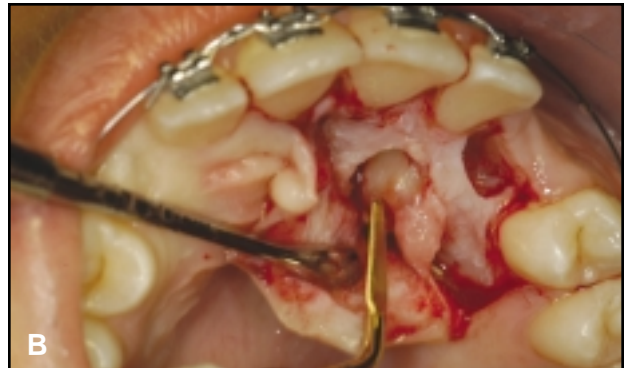
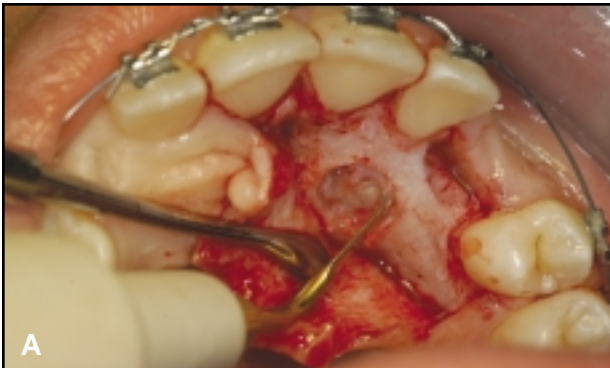
Fig. 5 A. Exposure of impacted canine crown using EX1 insert. B. Removal of follicle.

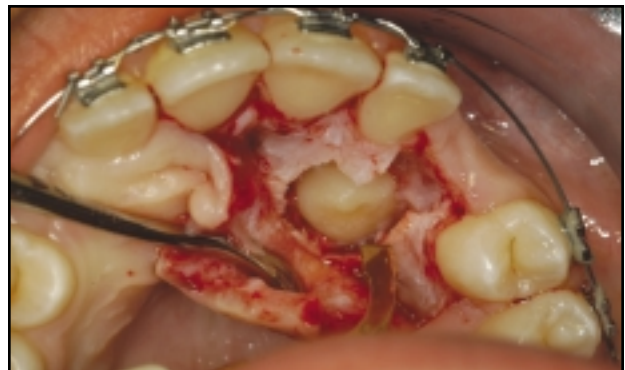
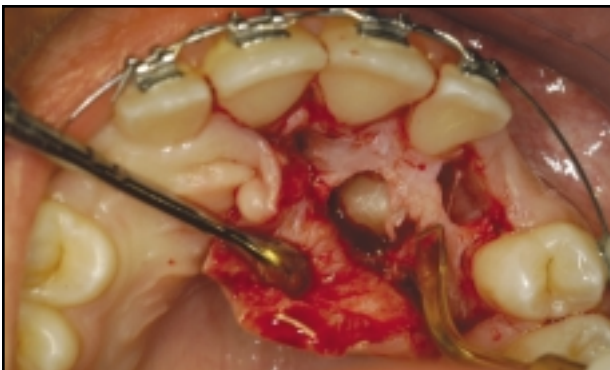
Fig. 6 Channel formed through alveolar bone using OT2 insert.

facilitate movement of the tooth during orthodontic repositioning.

A conventional bracket is bonded to the enamel surface of the exposed canine (Fig. 7). After the flap has been sutured, a window is opened with a scalpel in the palatal mucosa to expose the crown of the impacted tooth. The window is then sutured with disconnected points.

## Discussion

A precise surgical cut is extremely important when the crown of a palatally impacted maxillary canine is close to the roots or crowns of the central and lateral incisors, as often occurs. Traditional burs do not distinguish between the mineralization and hardness of the bone, the radicular cementum, and the enamel. Piezoelectric surgery is precise enough to account for such differences, thus avoiding damage to the adjacent teeth.

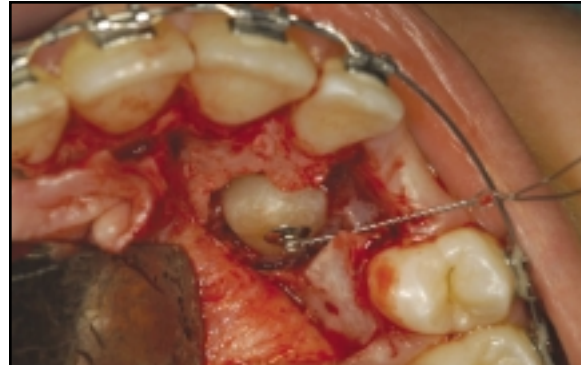The EX1 insert for the Mectron Piezo-surgery handpiece provides a good demarcation of the exposed crown. It also removes the follicle faster than manual instruments can, with no loss of cervical bone or consequent gingival recession.

The piezoelectric instrument controls bleeding during the surgical procedure, ensuring a dry field for bonding to the impacted tooth and eliminating the need for gauze sponges or electrocoagulation. Total surgical time is greatly reduced with this method.

The piezoelectric device is quieter than conventional handpieces, and it avoids the trauma associated with a manual hammer and chisel. Therefore, it improves both the comfort and the cooperation of the patient.

## REFERENCES

1. Chate, R.A.C.: Maxillary canine displacement: Further twists in the tale, *Eur. J. Orthod.* 25:43-47, 2003.
2. Chaushu, S.; Zilberman, Y.; and Becker, A.: Maxillary incisor impaction and its relationship to canine displacement, *Am. J.*



**Fig. 7** Bracket bonded to exposed canine crown.

- Orthod. 124:144-150, 2003.
3. Becker, A.; Sharabi, S.; and Chaushu, S.: Maxillary tooth size variation in dentitions with palatal canine displacement, *Eur. J. Orthod.* 24:313-318, 2002.
4. Chaushu, S.; Sharabi, S.; and Becker, A.: Dental morphologic characteristics of normal versus delayed developing dentitions with palatally displaced canines, *Am. J. Orthod.* 121:339-346, 2002.
5. Peck, S.; Peck, L.; and Kataja, M.: The palatally displaced canine as a dental anomaly of genetic origin, *Angle Orthod.* 64:249-256, 1994.
6. Peck, L.; Peck, S.; and Attia, Y.: Maxillary canine-first premolar transposition, associated dental anomalies and genetic basis, *Angle Orthod.* 63:99-109, 1993.
7. Becker, A.; Smith, P.; and Behar, R.: The incidence of anomalous maxillary lateral incisors in relation to palatally displaced cuspids, *Angle Orthod.* 51:24-29, 1981.
8. Jacoby, H.: The etiology of maxillary canine impaction, *Am. J. Orthod.* 84:125-132, 1983.
9. Becker, A.: Etiology of maxillary canine impaction (letter), *Am. J. Orthod.* 86:437-438, 1984.
10. Becker, A. and Chaushu, S.: Dental age in maxillary canine ectopia, *Am. J. Orthod.* 117:657-662, 2000.
11. Vercellotti, T.; Crovace, A.; Palermo, A.; and Molfetta, I.: The piezoelectric osteotomy in orthopedics: Clinical and histological evaluation (pilot study in animals), *Mediterr. J. Surg. Med.* 9:89-96, 2001.
12. Vercellotti, T.: Piezoelectric surgery in implantology: A case report—A new piezoelectric ridge expansion technique, *Int. J. Period. Restor. Dent.* 20:359-365, 2000.
13. Vercellotti, T.; De Paoli, S.; and Nevins, M.: The piezoelectric bony window osteotomy and sinus membrane elevation: Introduction of a new technique for simplification of the sinus augmentation procedure, *Int. J. Period. Restor. Dent.* 21:561-567, 2001.
14. Bovi, M.: Mobilization of the inferior alveolar nerve with simultaneous implant insertion: A new technique—A case report, *Int. J. Period. Restor. Dent.* (in press).